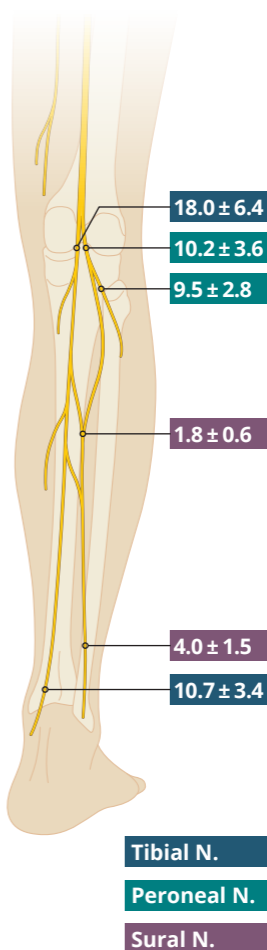
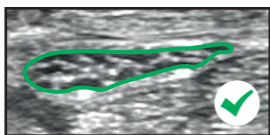
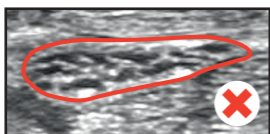
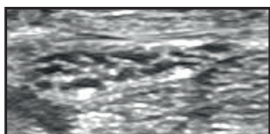
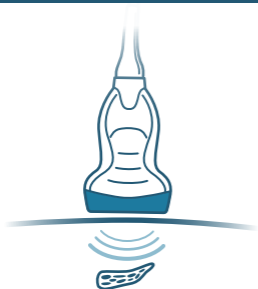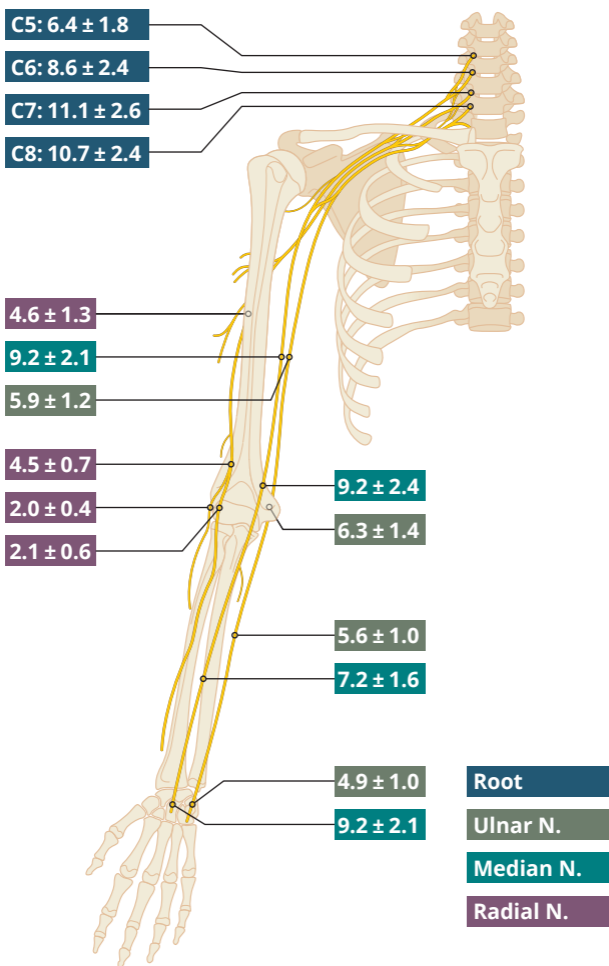


Correct measurement is obtained by tracing at the inner border of the hyperechoic rim (external epineurium) of the nerve.





Cross-sectional area: Mean \pm Standard Deviation in mm²

All information is supplied without guarantee. ©2018

A detailed description about which data from which studies were included, how and where you correctly measure the cross-sectional area and current versions of the pocketcard are available under pucmed.at/pocketcards